Tyler Wynne, DDS

Smile Design: A Modern Approach

Blending Analog and Digital Technologies

INTRODUCTION

Dentists today face exciting times with the advancement of smile design treatment planning options. Adaptation of a streamlined smile design process to ensure predictable aesthetics and function is a reality of the capacity of digital dentistry. Our patients are growing more sophisticated than ever and expect reliable treatment outcomes that can be visualized prior to proceeding with treatment. Although traditional analog treatment planning for comprehensive full-mouth rehabilitation is predictable with a hand-fabricated diagnostic wax-up, patients can become more involved from the beginning of treatment planning with a digital diagnosis and workflow.

Communication between the patient, the dental laboratory team, and the clinician can be facilitated in an effective manner using digital smile design and facially generated treatment planning concepts. A visual perception of improved dental and facial aesthetics and function, and a smile that reflects the patient's unique personality, motivates the patient by tapping into his or her emotions and enhances the experience and results for the patient, dentist, lab ceramist, and technician. Since digital smile design-proposed restorations in the correct x-, y-, and z-axes can be layered on either a 2- or 3-D image of the patient, computer-aided smile design software serves as a powerful communication tool.

The young patient in this case presented with obvious aesthetic and functional deficits associated with amelogenesis imperfecta (AI) (Figures 1 to 3). Through digital smile design and workflow, the quality of life and psychological health for young and tech-savvy patients can be positively impacted.

Figure 1. The patient presented with a desire to make an aesthetic improvement to her smile.

Figure 2. The patient's smile, showing effects of amelogenesis imperfecta on her dentition.

Figure 3. The retracted view, demonstrating malformed enamel and underdeveloped teeth.

CASE REPORT

Diagnosis and Treatment Plan

Whenever deciding on the appropriate time to initiate treatment, careful consideration must be given to the developmental growth stage of the patient, as well as the severity of AI and its impact on the psychological health of the patient. AI, which afflicts approximately 1 in 14,000 Americans, is a genetic condition that affects the structure of tooth enamel and the patient's visual appearance.[1,2] The diagnosis of AI is typically made through clinical presentation, with enamel defects being characterized as hypocalcified (damage to crystallite arrangement with future impaired growth) and hypoplastic (deficient quantity of enamel) and with hypomaturation (impairment in the final growth and development of enamel crystallites).[3,4] There are 4 main types of AI classifications, separated into categories based upon the type of defect, and 14 subtypes that are determined by clinical presentation and how the unique gene is inherited.[4,5] A constricted maxillary arch with a skeletal open bite with impaired occlusal stability has been associated with AI.[6-8]

In this case, the patient and her parents desired an aesthetic improvement to attain a higher quality of life and improved self-esteem. This patient had undergone 18 months of orthodontic treatment in preparation for a comprehensive restorative treatment phase. The arches had been aligned to provide a positioning of the teeth that would minimize unnecessary removal of tooth structure and be more ideal for prep design.

To begin the digital treatment planning, a full-face photo was taken with the patient smiling. Using 3Shape's smile design software, a digital intraoral scan of both arches can be taken or, as in this case, vinyl polysiloxane (VPS) impressions (Genie VPS rapid set light body and Genie VPS Putty heavy body impression materials [Sultan Healthcare]) can be obtained. Stone models were then poured up and scanned using the 3Shape D2000

continued on page 88

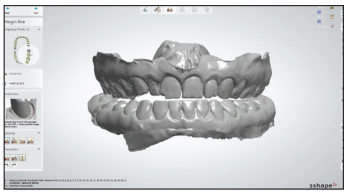

Figure 4. Digital models of the scanned stone models (3Shape D2000 laboratory scanner).

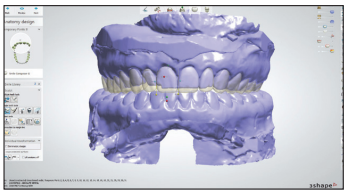

Figure 5. The 3Shape digital smile design, showing the idealized aesthetics and function of the maxillary arch.

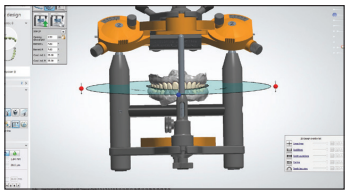

Figure 6. Virtual articulation was accomplished using the virtual SAM3 articulator (Great Lakes Orthodontics); proper anterior guidance and occlusion were established digitally.

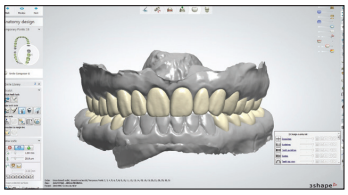

Figure 7. The finalized 3Shape digital smile design with the idealized function and aesthetics.

Figure 8. Superimposition of the 3-D digital smile design onto a 2-D photo of the patient.

Figure 9. The digitally designed idealized maxillary arch.

Figure 10. The digitally designed idealized mandibular arch.

Figure 11. Models of digitally designed restorations in VeroGlaze (MED620) 3-D acrylic printing material (Stratasys).

Figure 12. A translucent thermoplastic stent was used as a reduction guide to assess clearance.

Figure 13. The conservatively prepared maxillary arch.

Figure 14. The maxillary arch restorations.

Smile Design: A Modern Approach

continued from page 86

laboratory scanner (Figure 4). Proper dental facial treatment planning concepts—by first establishing the appropriate macro-aesthetics of maxillary incisal edge position, proper smile line, Curve of Spee, and fullness of the buccal corridors and then addressing the micro-aesthetics of youthful incisal embrasures and tooth shape—was completed with 3Shape's smile design software (Figures 5 to 7). Using reference points of the eyes, facial midline, and preoperative incisal edge position, the scanned 3-D models of the patient were superimposed onto the 2-D image of the patient's smiling face, and the idealized smile and digital wax-up was completed with a post-treatment digital smile rendering (Figure 8). Having the ability for the patient to see the new position and approximate postoperative appearance is a strong communication tool with meaningful use between the dentist, the lab ceramist and digital smile design technician, and the patient. In this case, GoToMeeting (LogMeIn), an online video conferencing software service, was utilized to involve the dentist, the lab ceramist and digital smile design technician, and the patient in the end aesthetic and functional goals.

The approved digital diagnostic wax-up and redesigned smile were then printed into a 3-D model using VeroGlaze (MED620) 3-D acrylic printing material (Stratasys) on the EDEN260VS Dental Advantage Stratasys 3-D printer (Stratasys) with an occlusal scheme that established anterior guidance with posterior disclusion on excursive movements (Figures 9 to 11).

Clinical Protocol

Treatment began by conservatively preparing the mandibular arch for 8 Envision high translucency monolithic zirconia crowns (Absolute Dental Lab, Durham, NC). Only the mandibular molars and premolars were prepared since the anterior sextant was not as affected by AI. Due to the patient's young age, minimal preparation design was crucial. The restorative material that was the most appropriate for the patient's functional and aesthetic goals was Envision high translucency monolithic zirconia (Absolute Dental Lab), requiring a minimal occlusal thickness of 0.8 mm. This very aesthetic material is the ideal blend of strength and beauty and, in the author's opinion, is visually indistinguishable from layered lithium disilicate. The ability to utilize CAD/CAM technology in the digital workflow and mill the restorations with high marginal and occlusal accuracy ensures predictability. To obtain ideal aesthetics and function, the digital diagnostic wax-up indicated the need to increase the vertical dimension of occlusion (VDO) by 1.0 mm.

...patients can become more involved from the beginning of treatment planning with a digital diagnosis and workflow.

After preparation of the mandibular arch using a round-ended diamond (No. 112-5161 [Henry Schein]), a centric bite registration was taken with a fast-set VPS bite registration material (Regisil Rigid Super Fast Set [Dentsply Sirona]), and the final impression was taken with Genie Rapid Set VPS putty and light body impression materials. To obtain hemostasis for the final impression, retraction paste (Expasyl [Kerr Dental]) was placed around the margins, left in place for 10 minutes, and then rinsed

Figure 15. A postoperative, full-face view of our patient, who was pleased with the outcome.

thoroughly with water and dried. A translucent thermoplastic matrix served as a reduction guide throughout the preparation and was used to fabricate the provisionals (Luxatemp [DMG America]). To achieve a natural, enamel-like appearance, a clear resin glaze material (LuxaGlaze [DMG America]) was applied to the provisionals and light cured with a plasma arc curing light (Sapphire Plus Plasma Arc [DenMat]).

The mandibular restorations were cemented with a bioactive luting cement (Ceramir Crown and Bridge [Doxa Dental]) that has the ability to form hydroxyapatite and create an alkaline environment to resist acid, ensuring long-term stability.

The patient returned the following week for preparation of the maxillary arch. Since the VDO was to be increased by 1.0 mm, and the deficient maxillary buccal corridors were to be filled by uprighting the canines and premolars, minimal-to-no facial and occlusal reduction was necessary on the maxillary arch. Margins were placed with a round-ended diamond (No. 112-5161 [Henry Schein]), interproximal contacts were cleared, a centric bite registration was obtained, and provisionalization was completed with the same protocol used for the mandibular arch (Figures 12 and 13). The models for both prepared arches were scanned using the D2000 laboratory scanner, and then the restorations were digitally designed and milled using the Roland DWX-51D (Roland DGA Corp) milling production unit (Figure 14).

The delivery of the final maxillary restorations progressed seamlessly, requiring no interproximal contact adjustments due to the preciseness of the digitally designed margins and the ideal contact design (Figure 15).

CLOSING COMMENTS

Our patients who come to us in search of aesthetic and functional improvements to their smiles want assurance of what they will look like after treatment. A proposed treatment outcome with a personalized digitally designed smile has the ability to emotionally influence and motivate our patients. Digital smile design is a valuable modern communication and diagnostic tool that is able to show what aspects of the smile are being addressed, why those identified aspects are being treated, and how the final result will resolve the aesthetic deficiencies present. Streamlining communication between the lab team, clinician, and patient benefits all of the parties involved.

The young woman in this case had multiple aesthetic deficiencies associated with AI that were addressed and resolved, improving the appearance of her smile and successfully transforming her self-esteem.✦

Acknowledgement: In the case presented, the digital smile design treatment planning and case collaboration involved the expert technical skills and artistic eyes of Maja Simonovic, digital smile designer; Drew Van Aarde and Conrad Rensburg, owners of Absolute Dental Lab in Durham, NC; Matt Vrhovac, technical lab manager; and their teams.

References

1. Aldred MJ, Savarirayan R, Crawford PJ. Amelogenesis imperfecta: a classification and catalogue for the 21st century. *Oral Dis*. 2003;9:19-23.
2. Witkop CJ, Sauk JJ. Heritable defects of enamel. In: Stewart RE, Prescott GH, eds. *Oral Facial Genetics*. St Louis, MO: Mosby; 1976;151-226.
3. Witkop CJ Jr. Amelogenesis imperfecta, dentinogenesis imperfecta and dentin dysplasia revisited: problems in classification. *J Oral Pathol*. 1988;17:547-553.
4. Wright JT. The diagnosis and treatment of dentinogenesis imperfecta and amelogenesis imperfecta. *Hellenic Dental Journal*. 1992;2:17-24.
5. Rowley R, Hill FJ, Winter GB. An investigation of the association between anterior open-bite and amelogenesis imperfecta. *Am J Orthod*. 1982;81:229-235.
6. Bäckman B, Adolfsson U. Craniofacial structure related to inheritance pattern in amelogenesis imperfecta. *Am J Orthod Dentofacial Orthop*. 1994;105:575-582.
7. Hoppenreijs TJ, Voorsmit RA, Freihofer HP. Open bite deformity in amelogenesis imperfecta. Part 1: an analysis of contributory factors and implications for treatment. *J Craniomaxillofac Surg*. 1998;26:260-266.
8. Aren G, Ozdemir D, Firatli S, et al. Evaluation of oral and systemic manifestations in an amelogenesis imperfecta population. *J Dent*. 2003;31:585-591.

Dr. Wynne received his DDS in 2014 from the University of North Carolina School of Dentistry, where he is also an adjunct member of the faculty. He practices general dentistry in Clemmons, NC, and is a scholar of The Dawson Academy. He is a member of the American Society for Dental Aesthetics and a Fellow of the International Academy of Dental-Facial Esthetics and the AGD. He can be reached via email at wtwynne@gmail.com.

Disclosure: Dr. Wynne reports no disclosures.