Tyler Wynne, DDS

William P. D. Wynne, DDS

Creating a More Youthful Smile

The patient who is presented in this clinical case report article came into our office to share her concerns about the appearance of her teeth and to seek appropriate care. She was unhappy with the color of her dentition, the excessive amount of gingival tissue exposed when she smiled, and the significant wear and crowding present (Figure 1). A more youthful looking smile was her desired objective. Smiles can show physical and aesthetic signs of aging, and as our patients get older and keep more of their natural teeth, age-related changes of the dentition are one the main challenges of modern aesthetic dentistry.[1]

CASE REPORT

Diagnosis and Treatment Planning

Figures 2 and 3 show the multiple aesthetic issues that would need to be addressed. The excessive wear accentuated the excessive gingival exposure and gummy smile. Occlusal and cervical wear due to attrition, abfraction, and biocorrosion has been a problem for years.[2] Due to the largely aprismatic/irregular enamel crystal form in the cervical region of her teeth along with the presence of a lower salivary pH with stress-induced tooth flexure, noncarious cervical abfraction lesions had developed.[3,4] Therefore, she had to accept full-coverage restorations (PFMs) on many of her posterior teeth throughout the years. The uneven incisal edges, absence of rounded incisal embrasures, and straight-line incisal edge contour contributed to the aged appearance of this smile. The lack of adequate oral hygiene and gingivitis that was now present may have been generated by the disconnect due to the aesthetic deficits. It is always interesting to see how the hygiene and gingival tissue respond after the aesthetic deficits have been resolved. Another complicating factor was the presence of an anterior tongue thrust due to her swallowing pattern, which prevented anterior occlusal contacts.

To address the multiple aesthetic concerns, our treatment plan called for 12 maxillary restorations (PFMs on teeth Nos. 2, 3, 14, and 15; all-ceramic veneers on teeth Nos. 7 to 9; and all-ceramic crowns on teeth Nos. 5, 6, 10, 11, and 12) and 12 mandibular restorations (PFMs on teeth Nos. 18, 19, 20 and 29, 30 and 31: all-ceramic veneers on teeth Nos. 22, 23, 26, and 27; and all-ceramic crowns on teeth Nos. 24 and 25).

Clinical Protocol

To prepare the mandibular teeth, we first corrected the anteroposterior arch form prior to placing depth cuts. A permanent marker was used to outline the excessive tooth structure that needed to be removed (Figure 4) to achieve a dentition that would be in same arch form. A depth cut technique was used (with a goal of 0.8 mm facial reduction) by using a 0.5-mm depth cut diamond No. 900-7136 (Henry Schein). The depth of the initial cut was marked with a permanent marker, as this is the most accurate method to ensure a specific reduction, and the round-ended diamond No. 112-5161 (Henry Schein) was used to remove the enamel. A 0.3-mm depth cut diamond No. 900-7135 (Henry Schein) was used to achieve a total reduction of 0.8 mm with the round-ended diamond utilized to reduce the last 0.3 mm of tooth structure. Since our target incisal reduction was 1.5 mm, and the round-ended diamond has a diameter of 0.75 mm at the tip, we sink this diamond twice its tip diameter to ensure a 1.5-mm reduction. To finalize the preparations, the external line angles were rounded/smoothed, clearance of the interproximal contacts was achieved, and the preps were then polished using a diamond (No. 8878K-31 [Brasseler USA]). By

Figure 1. Pre-op frontal view.

Figure 2. Excessive gum display. **(a)** Frontal view. **(b)** Right lateral view. **(c)** Left lateral view.

preparing the teeth with cleared contacts, we gained several advantages: our technician would have control in placing and correcting misaligned midlines, alterations in color could be made in this area to mimic natural teeth, the lingual margin was placed in a free cleansing area, and retention form was increased.

After the mandibular teeth were prepped, a centric relation registration bite was taken using red PATTERN RESIN (GC America). This is an extremely hard material that is an excellent choice for taking and verifying accurate bite registrations. A model of the master wax-up was made, and a themoplastic matrix was then prepared over it to fabricate the temporaries. An additional 3-piece wax bite (DeLar) was taken. A one-piece Luxatemp (DMG America) temporary was fabricated, and Figure 5 shows the temporary at the time of cementation of the definitive restorations. The patient had been using a 0.12% chlorhexidine gluconate (Peridex [3M]) oral rinse (as directed) during temporization due to her history of poor oral hygiene; thus marginal staining was present. (Brushing with the rinse can reduce the amount of staining.) The completed mandibular restorations were mounted on the Sam 3 Articulator (Great Lakes Orthodontics) in centric relation position.

A desired incisal reduction of 1.5 to 2.0 mm was obtained by sinking the tip of the round-ended diamond twice its diameter.

A few days after insertion, the mandibular restorations are shown (Figure 6), and within a week, the gingiva had healed.

In evaluation of the maxillary arch, tooth No. 7 was facial to ideal arch form due to a linguoversion of the root (Figure 7). The occlusal view with permanent ink markings seen in Figure 7 indicates how much tooth structure was out of position and identified how much adjustment would be necessary before beginning the depth cuts for the remaining anterior teeth. After the reduction of No. 7, all anterior teeth were in the desired arch form.

We began the depth cuts for the final preparation of the maxillary teeth in a similar manner as the mandibular preps. Our desired total facial plane of reduction was 0.8 mm. The depth of the 0.5-mm cut was marked with a permanent marker, so that once the enamel was reduced, exactly 0.5 mm reduction would be ensured. This was done again for the 0.3-mm depth cut for a total of 0.8 mm reduction. The interproximal reduction was extended to the lingual aspect of each tooth for the reasons mentioned previously. A desired incisal reduction of 1.5 to 2.0 mm was obtained by sinking the tip of the round-ended diamond twice its diameter. Maxillary incisal edges were parallel not only to the mandibular incisal edges, but to the interpupillary line as well as the floor. All external line angles were polished using a suitable polishing point (OneGloss 060 [Shofu Dental]) to make the preps as smooth as possible (Figure 8). Red PATTERN RESIN was used to capture the bite, centric relation, and vertical dimension of occlusion at the same time (Figure 9). After all the maxillary teeth were prepared, the anterior teeth were impressed without retraction cord, with a 2-cord technique utilized for the posterior preps. Dr. Bob Nixon's temporary technique was employed to fabricate the temporaries for the maxillary arch. A rubber-like material (Rapid Simplified Veneer Provisionals or RSVP [Cosmedent]) was adapted to the master wax-up to

Figure 3. (a) Frontal view showing excessive wear, exposed margins, with cervical abfraction lesions. **(b)** Right lateral view showing excessive wear. **(c)** Left lateral view showing excessive wear.

Figure 4. Occlusal view showing tooth structure to be removed first in order to form a smoother arch.

Figure 5. Frontal view showing mandibular temporaries in place on day of cementation of definitive restorations.

Figure 6. Frontal view showing mandibular restorations recently bonded.

Figure 7. Occlusal view showing location of malpositioned tooth structure. To make a smooth arch, the tooth structure identified with green marker must be removed.

Figure 8. Frontal view showing the preps being polished with a OneGloss 060 (Shofu Dental) polishing point.

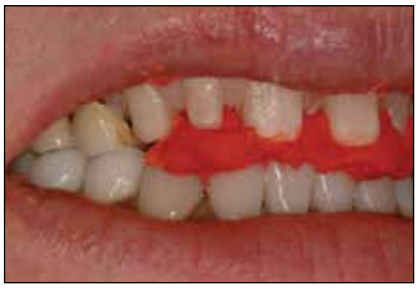

Figure 9. Right lateral view showing red PATTERN RESIN (CG America) in place.

Figure 10. Frontal view of Rapid Simplified Veneer Provisionals (RSVP [Cosmedent]) material used in temporary fabrication.

Figure 11. (a) Frontal view of completed case (Authentic [Ceramay] pressable all-ceramic system). **(b)** Right lateral view of completed case. **(c)** Left lateral view of completed case.

capture all aesthetic and functional lingual and incisal contours (Figure 10). The gingival one third of the facial aspect of the RSVP material was removed, and RSVP low-viscosity incisal composite resin was then placed into the matrix. Next, the low-viscosity incisal composite resin was light-cured (Rembrandt Sapphire Plasma Arc curing light [DenMat]), leaving the operator to hand place and contour the high-viscosity cervical RSVP composite resin to the facial margins with accuracy.

Figure 12. Completed case.

It should be noted that our restorative material choice had to be based upon creating not only the strongest restoration, but also a material that would be compatible with the mechanical, biologic, and optical properties of the underlying dental tissues.[1] The Authentic (Ceramay) pressable all-ceramic system was selected due to its strength, superior optical properties, conservative prep design, and its plus-plus ingot shade, which was ideal for blocking out any discolored teeth.

CLOSING COMMENTS

In this case, we minimized the patient's gingival exposure and obtained a balance between the restorations and soft tissues by re-establishing a more aesthetic width-to-height ratio of her anterior dentition. The aged occlusal and cervical wear of her teeth was transformed into a more youthful-looking result with rounded incisal embrasures. We also improved the color of her teeth and eliminated crowding to achieve a desired youthful-looking smile (Figures 11 and 12). The patient, as well as the dental and dental laboratory teams, were all very pleased with the outcome.✦

Acknowledgment

The authors would like to acknowledge that the laboratory fabrication of the restorations was done by John Wilson, Wilson Dental Arts (Raleigh, NC).

References

1. Magne P, Belser U. *Bonded Porcelain Restorations in the Anterior Dentition: A Biomimetic Approach*. Chicago, IL: Quintessence Publishing; 2002.
2. Grippo JO, Simring M, Coleman TA. Abfraction, abrasion, biocorrosion, and the enigma of non-carious cervical lesions: a 20-year perspective. *J Esthet Restor Dent*. 2012;24:10-23.
3. Grippo JO. Abfractions: a new classification of hard tissue lesions of teeth. *J Esthet Dent*. 1991;3:14-19.
4. Poole DF, Newman HN, Dibdin GH. Structure and porosity of human cervical enamel studied by polarizing microscopy and transmission electron microscopy. *Arch Oral Biol*. 1981;26:977-982.

Dr. Tyler Wynne, a 2014 graduate of the University of North Carolina School of Dentistry, practices general dentistry in Faison, NC, and is adjunct faculty at the University of North Carolina School of Dentistry. He can be reached via email at wtwynne@gmail.com.

Dr. William Wynne maintains a private practice in Raleigh, NC, focusing on aesthetic and restorative dentistry. He graduated from the University of North Carolina School of Dentistry (1971) and has achieved the status of Pankey Scholar. He is a Fellow of the American Society for Dental Aesthetics and a member of the American Society of Dental Practice Administration. He has published numerous articles on aesthetic dentistry, occlusion, and eating disorders. He can be reached at (919) 851-3716.

Disclosure: The authors report no disclosures.